Research Article

Academia Journal of Medicine
Vol.9 (2) July - December 2026

Orthodontic Camouflage Management of Bimaxillary Dentoalveolar Protrusion using Four First Premolar Extractions and Differential Space Closure Mechanics: A Case Report

Zaiba Nagori[1*], **Zeel Desai**[2], **Mahesh Jain**[3], **Kaushal Shah**[4], **Shrinidhi Thakkar**[1] and **Nidhi Barad**[1]

[1]*Postgraduate Student, Department of Orthodontics and Dentofacial Orthopedics, AMC Dental College and Hospital, Ahmedabad, India*
[2]*Private Consultant (M.D.S Orthodontics and Dentofacial Orthopedics), India*
[3]*Reader, Department of Orthodontics and Dentofacial Orthopedics, AMC Dental College and Hospital, Ahmedabad, India*
[4]*Senior Lecturer. Department of Orthodontics and Dentofacial Orthopedics, AMC Dental College and Hospital, Ahmedabad, India.*

* Corresponding author. E-mail: zaibanagori23@gmail.com

https://doi.org/10.48165/ajm.2026.9.02.11

ARTICLE INFO

Article history:
Published 2026

Keywords:
Camouflage orthodontics
Bimaxillary dentoalveolar protrusion
Four first premolar extraction
MBT appliance
T-loop mechanics
Sliding mechanics
Anchorage control

ABSTRACT

Bimaxillary dentoalveolar protrusion is characterized by proclination and protrusion of the maxillary and mandibular incisors despite a relatively harmonious underlying skeletal relationship. In adult patients with limited or no remaining growth potential, orthodontic camouflage using extraction therapy is an effective approach for correcting dentoalveolar protrusion while preserving the existing skeletal pattern. This case report describes the orthodontic management of a 21-year-old male with skeletal Class I malocclusion, prognathic maxilla and mandible, horizontal growth pattern, and pronounced bimaxillary incisor proclination and protrusion. The treatment involved extraction of all four first premolars followed by fixed orthodontic treatment using a 0.018-inch MBT preadjusted edgewise appliance. Maximum anchorage was reinforced using a transpalatal arch in the maxillary arch and incorporation of the second molars into the posterior anchorage units. Maxillary anterior retraction was performed using continuous T-loop mechanics, while mandibular space closure was achieved using controlled sliding mechanics. Treatment resulted in substantial correction of maxillary and mandibular incisor proclination, normalization of the interincisal relationship, maintenance of the skeletal Class I relationship and horizontal growth pattern, and improvement in dental esthetics. A stable Class I molar and canine relationship with satisfactory overjet, overbite, intercuspation, and root parallelism was achieved. The case demonstrates that careful diagnosis, maximum anchorage control, and individualized biomechanical planning can provide predictable and stable outcomes in adult patients with bimaxillary dentoalveolar protrusion.

INTRODUCTION

Bimaxillary dentoalveolar protrusion is a commonly encountered orthodontic condition characterized by excessive proclination and protrusion of the maxillary and mandibular incisors in the presence of a relatively harmonious skeletal relationship. The condition may be associated with prominent lips, altered smile esthetics, and an unfavorable anterior tooth display. [1–3]

Although the underlying skeletal relationship may be within acceptable limits, the excessive dentoalveolar inclination of the incisors can significantly affect facial appearance and the patient's perception of dental esthetics.

[1,2]

In adult patients, treatment is primarily directed toward dentoalveolar correction because active craniofacial growth is essentially complete. Consequently, orthodontic camouflage is often preferred when the skeletal discrepancy is limited and the facial profile is acceptable. [2,4,5] The treatment objective is to reposition and upright the anterior teeth while maintaining the existing skeletal relationship and preserving facial harmony. The decision to extract teeth depends on the degree of incisor proclination, the amount of space required for anterior retraction, the soft tissue profile, periodontal considerations, and the desired final incisor position. [1,2,6]

Extraction of the four first premolars provides substantial space for controlled retraction of both anterior segments and remains an effective treatment option for patients with significant bimaxillary dentoalveolar protrusion. [6–9] However, the success of extraction-based camouflage depends greatly on anchorage preservation. When maximum anterior retraction is required, unwanted mesial movement of the posterior teeth must be minimized to ensure that the extraction spaces are used efficiently. [6,8,10]

Various anchorage reinforcement methods may be used, including transpalatal arches, Nance appliances, temporary anchorage devices, extraoral traction, and incorporation of additional posterior teeth into the anchorage unit. [1,10–12] In addition, the choice of space closure mechanics influences the quality and predictability of tooth movement. Frictionless mechanics using T-loop springs allow controlled force systems and favorable moment-to-force ratios, whereas sliding mechanics provide efficient space closure when used with rigid archwires and appropriate torque control. [13–15]

The present case report describes the orthodontic management of an adult patient with skeletal Class I malocclusion and bimaxillary dentoalveolar protrusion using extraction-based camouflage therapy. The treatment involved four first premolar extractions, maximum anchorage reinforcement, continuous T-loop mechanics for maxillary anterior retraction, and sliding mechanics for mandibular space closure

CASE REPORT

A 21-year-old male reported to the Department of Orthodontics with the chief complaint of forwardly placed upper and lower front teeth affecting his smile and facial esthetics. The patient was medically fit and had no significant medical or dental history. There was no history of previous orthodontic treatment or temporomandibular joint dysfunction.

Extraoral examination revealed a symmetrical face with a straight facial profile, competent lips at rest, and an increased nasolabial angle. The patient exhibited a horizontal facial growth pattern with satisfactory facial proportions. Intraoral examination revealed bilateral Angle's Class I molar and canine relationships. The maxillary and mandibular incisors were markedly proclined and protrusive. Overjet and overbite were within normal limits, and the dental arches were coordinated without any transverse discrepancy.

Pretreatment records included extraoral and intraoral photographs, study models, a panoramic radiograph, and a lateral cephalogram. Comprehensive clinical and cephalometric evaluation confirmed a skeletal Class I relationship associated with prognathic maxilla and mandible, a horizontal growth pattern, and pronounced bimaxillary dentoalveolar protrusion. Based on the clinical findings, extraction camouflage treatment was planned with maximum anchorage to facilitate controlled retraction of the anterior teeth while maintaining the existing skeletal relationship and facial profile. [2,6,9]

DIAGNOSIS AND ETIOLOGY

The patient was diagnosed with Angle's Class I malocclusion on a skeletal Class I base, associated with a prognathic maxilla and mandible, horizontal growth pattern, and severe bimaxillary dentoalveolar protrusion. Cephalometric analysis revealed an SNA angle of 89°, an SNB angle of 85°, and an ANB angle of 4°, indicating a harmonious sagittal maxillomandibular relationship. The Wits appraisal of +2 mm further supported the skeletal Class I relationship. Vertical skeletal assessment showed an FMA of 14°, SN-GoGn angle of 26°, and Y-axis angle of 57°, consistent with a horizontal growth tendency and favorable vertical proportions.

The dental analysis demonstrated pronounced proclination and protrusion of the maxillary and mandibular incisors. The maxillary incisors exhibited a U1-SN angle of 126°, U1-NA angle of 36°, and U1-NA linear measurement of 8 mm. The mandibular incisors demonstrated an IMPA of 113°, L1-NB angle of 39°, and L1-NB linear measurement of 12 mm. The interincisal angle was reduced to 104°, confirming excessive proclination of both anterior segments. The soft tissue profile was straight, with competent lips and an increased nasolabial angle of 110°.

The malocclusion was primarily dentoalveolar in origin. Excessive proclination and protrusion of the maxillary and mandibular incisors occurred on an otherwise favorable skeletal base. Since the patient was 21 years old and had completed active craniofacial growth, growth modification was not indicated. The treatment approach was therefore directed toward extraction-based orthodontic camouflage to correct the dentoalveolar discrepancy while preserving

the underlying skeletal relationship and facial balance. [2,4,6]

Treatment Objectives

· To correct the proclination and protrusion of the maxillary and mandibular incisors.

· To achieve ideal axial inclination and appropriate torque control of the anterior teeth.

· To establish optimal overjet and overbite with proper anterior guidance.

· To maintain the existing skeletal Class I relationship and horizontal growth pattern.

· To preserve the straight soft tissue profile while improving dental esthetics.

· To achieve a functional, stable, and periodontally healthy occlusion.

Treatment Progress

Following informed consent, all four first premolars were extracted to provide adequate space for correction of the pronounced bimaxillary dentoalveolar protrusion. A 0.018-inch MBT preadjusted edgewise appliance was bonded in both arches. [1,6,10]

Because maximum anterior retraction was planned, Group A anchorage was established. A transpalatal arch was used for reinforcement of maxillary posterior anchorage, while the maxillary and mandibular second molars were banded and incorporated into the posterior anchorage units to minimize unwanted mesial movement during space closure. [9–12]

Initial alignment and leveling were performed using sequential nickel-titanium archwires progressing from 0.014-inch NiTi to 0.016-inch NiTi, followed by 0.016 × 0.022-inch NiTi for further leveling and torque expression. Working archwires consisted of 0.016 × 0.022-inch stainless steel in both arches. [1,10]

Maxillary anterior retraction was performed using continuous T-loop mechanics. The T-loop design was selected to provide a favorable moment-to-force ratio and controlled movement of the anterior segment while preserving posterior anchorage. The mechanics allowed gradual retraction and uprighting of the maxillary incisors with control over the movement of the anterior segment. [11,13,14]

In the mandibular arch, extraction space closure was performed using sliding mechanics on rectangular stainless steel archwires. Controlled force application was used to achieve efficient retraction while maintaining adequate anterior torque. Space closure was monitored at regular intervals, and adjustments were made to maintain the desired force system and tooth position. [10,15]

Finishing procedures included settling elastics to improve final intercuspation. After the desired occlusal relationship was achieved, the fixed appliances were debonded and appropriate retention was instituted. [1,2]

Treatment Results

The planned treatment objectives were successfully achieved. The maxillary and mandibular incisors were substantially retracted and uprighted, resulting in improved anterior tooth inclination and a more favorable interincisal relationship. Bilateral Class I molar and canine relationships were maintained, and ideal overjet and overbite were established with satisfactory anterior guidance.

The underlying skeletal relationship remained essentially unchanged, confirming the predominantly dentoalveolar nature of the treatment effects. The SNA remained at 89°, SNB at 85°, ANB at 4°, Wits appraisal at +2 mm, and FMA at 14°. The horizontal growth pattern and favorable vertical facial proportions were preserved throughout treatment.

Significant correction of the maxillary incisor inclination was achieved. The U1-SN angle decreased from 126° to 112°, the U1-NA angle decreased from 36° to 22°, and the linear U1-NA measurement reduced from 8 mm to 3 mm. These changes demonstrated effective controlled retraction and improvement in the axial inclination of the maxillary incisors.

The mandibular incisors also showed marked improvement. The IMPA decreased from 113° to 97°, while the L1-NB angle decreased from 39° to 23°. The linear L1-NB measurement reduced from 12 mm to 3 mm, indicating substantial correction of mandibular incisor proclination and protrusion.

The interincisal angle increased from 104° to 132°, reflecting normalization of the relationship between the maxillary and mandibular incisors. Soft tissue evaluation demonstrated maintenance of the straight facial profile, with a slight increase in the nasolabial angle from 110° to 113°. This reflected favorable soft tissue adaptation following anterior retraction without compromising facial harmony.

Post-treatment panoramic radiographic evaluation demonstrated satisfactory root parallelism without clinically significant external apical root resorption or periodontal compromise. Stable intercuspation, appropriate anterior guidance, and mutually protected occlusion were achieved. Overall, the treatment produced a functional, stable, and esthetically favorable result. (fig 6)

Figure 6. Post debonding photographs

DISCUSSION

The successful management of adult patients with bimaxillary dentoalveolar protrusion requires accurate diagnosis and careful differentiation between skeletal and dentoalveolar components. [1–4] In the present patient, the skeletal relationship was harmonious, with a skeletal Class I pattern despite prognathic maxillary and mandibular bases. The primary problem was the excessive proclination and protrusion of the anterior teeth. Because active growth was no longer available for modification and the facial profile was acceptable, orthodontic camouflage was selected as the most appropriate treatment approach. [2,4–6]

Extraction of all four first premolars provided the space necessary for controlled retraction of both anterior segments. The use of extraction therapy allowed correction of the excessive incisor inclination while maintaining the underlying skeletal relationship. This was particularly important in the present case because the treatment objective was not to alter the skeletal pattern but to correct the dentoalveolar protrusion and improve dental esthetics. [6–9]

Anchorage control was a critical component of treatment. Maximum anterior retraction requires effective preservation of the posterior anchorage unit because unwanted mesial movement of the posterior teeth reduces the amount of space available for anterior correction. [9–12] In this case, the transpalatal arch and incorporation of the second molars into the anchorage unit provided additional reinforcement. This approach permitted effective utilization of the extraction spaces for anterior retraction while maintaining the existing molar relationship. [9,10,12]

Different space closure mechanics were selected for the two arches according to the biomechanical requirements. Continuous T-loop mechanics were used in the maxillary arch because they provide frictionless space closure and allow favorable control of the moment-to-force ratio. This was particularly advantageous for controlled retraction and uprighting of the markedly proclined maxillary incisors. [11,13,14] In contrast, sliding mechanics were used in the mandibular arch to provide efficient space closure on rigid rectangular stainless steel archwires while maintaining adequate torque control. [10,15]

The treatment changes were predominantly dentoalveolar, as demonstrated by the stability of the skeletal cephalometric parameters. The SNA, SNB, ANB, Wits appraisal, and FMA remained essentially unchanged. This stability confirms that the treatment achieved its objectives through controlled orthodontic tooth movement rather than skeletal alteration, which is consistent with the expected response in an adult camouflage case. [2,6]

The most notable changes were observed in the inclination and position of the anterior teeth. The reduction in U1-SN, U1-NA, and U1-NA linear measurements demonstrated effective correction of maxillary incisor proclination and protrusion. Similarly, the reduction in IMPA, L1-NB angle, and L1-NB linear measurement demonstrated substantial improvement in mandibular incisor position. The increase in the interincisal angle further confirmed the normalization of the anterior tooth relationship. [3,6–8]

The soft tissue response was favorable. The straight facial profile was maintained, and the slight increase in the nasolabial angle reflected the improvement in maxillary incisor position. Importantly, the treatment achieved dental correction without producing undesirable alteration of the overall facial profile. This emphasizes the importance of individualized treatment planning and appropriate control of the amount and direction of anterior retraction. [2,5,6]

The post-treatment findings also demonstrated the importance of finishing and retention. Satisfactory root parallelism, stable intercuspation, proper anterior guidance, and mutually protected occlusion were achieved. These outcomes suggest that appropriate anchorage reinforcement, controlled force application, and careful finishing can provide predictable results in adult extraction-based camouflage treatment. [1,10]

From a clinical perspective, this case highlights that the treatment of bimaxillary dentoalveolar protrusion should be based on the relationship between the skeletal pattern, dental inclinations, soft tissue profile, and the amount of retraction required. In patients with a favorable skeletal relationship and significant incisor proclination, four first premolar extraction therapy can provide sufficient space for comprehensive correction. However, the success of treatment depends on precise biomechanics and preservation of anchorage throughout space closure. [1,2,6,9–14]

CLINICAL SIGNIFICANCE

· Extraction-based camouflage is an effective treatment

option for adult patients with skeletal Class I malocclusion and bimaxillary dentoalveolar protrusion.

· Four first premolar extractions provide adequate space for controlled correction of pronounced maxillary and mandibular incisor proclination.

· Maximum anchorage reinforcement using a transpalatal arch and incorporation of second molars can minimize posterior anchorage loss in appropriately selected patients.

· Continuous T-loop mechanics provide controlled maxillary anterior retraction with favorable biomechanical control.

· Sliding mechanics can provide efficient mandibular space closure when combined with rigid archwires and adequate torque control.

· Individualized biomechanical planning is essential for achieving stable occlusal, functional, and esthetic outcomes.

CONCLUSION

Orthodontic camouflage using extraction of all four first premolars was an effective treatment approach for this adult patient with skeletal Class I malocclusion and pronounced bimaxillary dentoalveolar protrusion. Maximum anchorage reinforcement, combined with continuous T-loop mechanics for maxillary anterior retraction and sliding mechanics for mandibular space closure, enabled controlled correction of the anterior dentoalveolar discrepancy while maintaining the underlying skeletal relationship.

The treatment resulted in substantial improvement in maxillary and mandibular incisor inclination and position, normalization of the interincisal relationship, maintenance of a balanced soft tissue profile, and establishment of stable functional occlusion. The case demonstrates that accurate diagnosis, appropriate extraction planning, effective anchorage control, and individualized biomechanics are essential for achieving predictable and esthetically favorable outcomes in adult patients requiring extraction-based orthodontic camouflage.

Figure 1. Pre-treatment photograph

Figure 2. Treatment mechanics

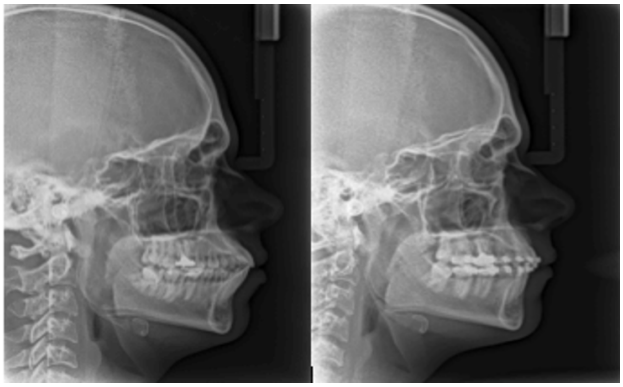

Figure 3. Cephalometric comparison

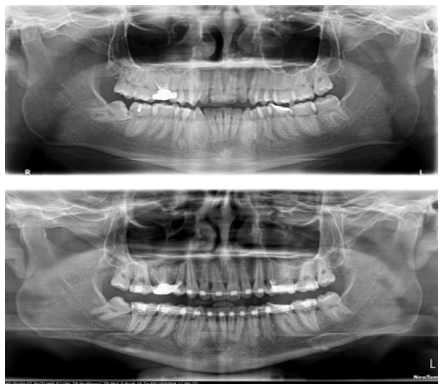

Figure 4. Panoramic comparision

Figure 5. Treatment progress

REFERENCES

Proffit, W. R., Fields, H. W., Jr., Larson, B. E., & Sarver, D. M. (2019). *Contemporary orthodontics* (6th ed.). Elsevier.

Bishara, S. E. (2001). *Textbook of orthodontics*. W. B. Saunders.

Bills, D. A., Handelman, C. S., & BeGole, E. A. (2005). Bimaxillary dentoalveolar protrusion: Traits and orthodontic correction. *The Angle Orthodontist, 75*(3), 333–339.

Ackerman, J. L., & Proffit, W. R. (1997). Soft tissue limitations in orthodontic treatment planning. *The Angle Orthodontist, 67*(5), 327–336.

Proffit, W. R., & Phillips, C. (1991). Adult orthodontic treatment: Current concepts and rationale. *American Journal of Orthodontics and Dentofacial Orthopedics, 100*, 192–198.

Tweed, C. H. (1944). Indications for the extraction of teeth in orthodontic procedure. *American Journal of Orthodontics, 30*, 405–428.

Dewel, B. F. (1955). The first premolar extraction debate. *American Journal of Orthodontics, 41*, 107–120.

Kim, T. K., Kim, J. T., & Mah, J. (2005). Extraction versus non-extraction treatment effects in bimaxillary protrusion. *American Journal of Orthodontics and Dentofacial Orthopedics, 127*, 539–547.

Upadhyay, M., Yadav, S., & Patil, S. (2008). Mini-implant anchorage versus conventional anchorage in extraction patients. *American Journal of Orthodontics and Dentofacial Orthopedics, 134*(1), 18–24.

Nanda, R. (2005). *Biomechanics and esthetic strategies in clinical orthodontics*. Elsevier.

Burstone, C. J. (1962). The rationale of the segmented arch technique. *American Journal of Orthodontics, 48*, 805–822.

Zachrisson, B. U. (1976). Clinical implications of anchorage control in orthodontics. *American Journal of Orthodontics, 70*, 410–421.

Burstone, C. J., & Koenig, H. A. (1976). Optimizing anterior and canine retraction with T-loop springs. *American Journal of Orthodontics, 70*(1), 1–19.

Burstone, C. J. (1981). Variable-modulus orthodontics. *American Journal of Orthodontics, 80*, 1–16.

Kusy, R. P., & Whitley, J. Q. (1997). Friction between different orthodontic archwire–bracket combinations. *The Angle Orthodontist, 67*(4), 293–302.

McLaughlin, R. P., Bennett, J. C., & Trevisi, H. J. (2001). *Systemized orthodontic treatment mechanics*. Mosby.

Graber, L. W., Vanarsdall, R. L., Vig, K. W. L., & Huang, G. J. (2017). *Orthodontics: Current principles and techniques* (6th ed.). Elsevier.

Burstone, C. J. (2012). Biomechanical foundation of clinical orthodontics. In T. M. Graber, R. L. Vanarsdall, & K. W. L. Vig (Eds.), *Orthodontics: Current principles and techniques* (5th ed.). Mosby.

How to Cite this Article: Nagori Z., Desai Z., Jain M., Shah K., Thakkar S., Barad N.. (2026). Orthodontic Camouflage Management of Bimaxillary Dentoalveolar Protrusion using Four First Premolar Extractions and Differential Space Closure Mechanics: A Case Report. *AJM*, ***9***(2), 58-63. https://doi.org/10.48165/ajm.2026.9.02.11